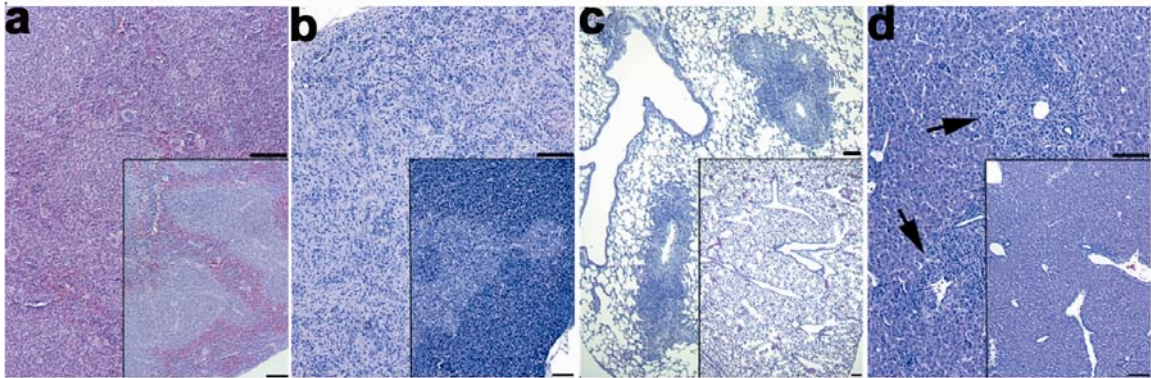


Supplementary Figure 2



Supplementary Figure 2. Disrupted lymphoid tissues and perivascular infiltrates in non-hematopoietic tissues in *Nor-1^{-/-}Nur77^{-/-}* mice. Hematoxylin and eosin staining revealed disruption of lymphoid architecture in spleen (a), thymus (b) and extensive perivascular infiltration into lung (c) and liver (d, insets show normal tissues, scale bar, 100 μm). Black arrows indicate perivascular infiltrates in liver. Analyses were performed at age 2–3 weeks.